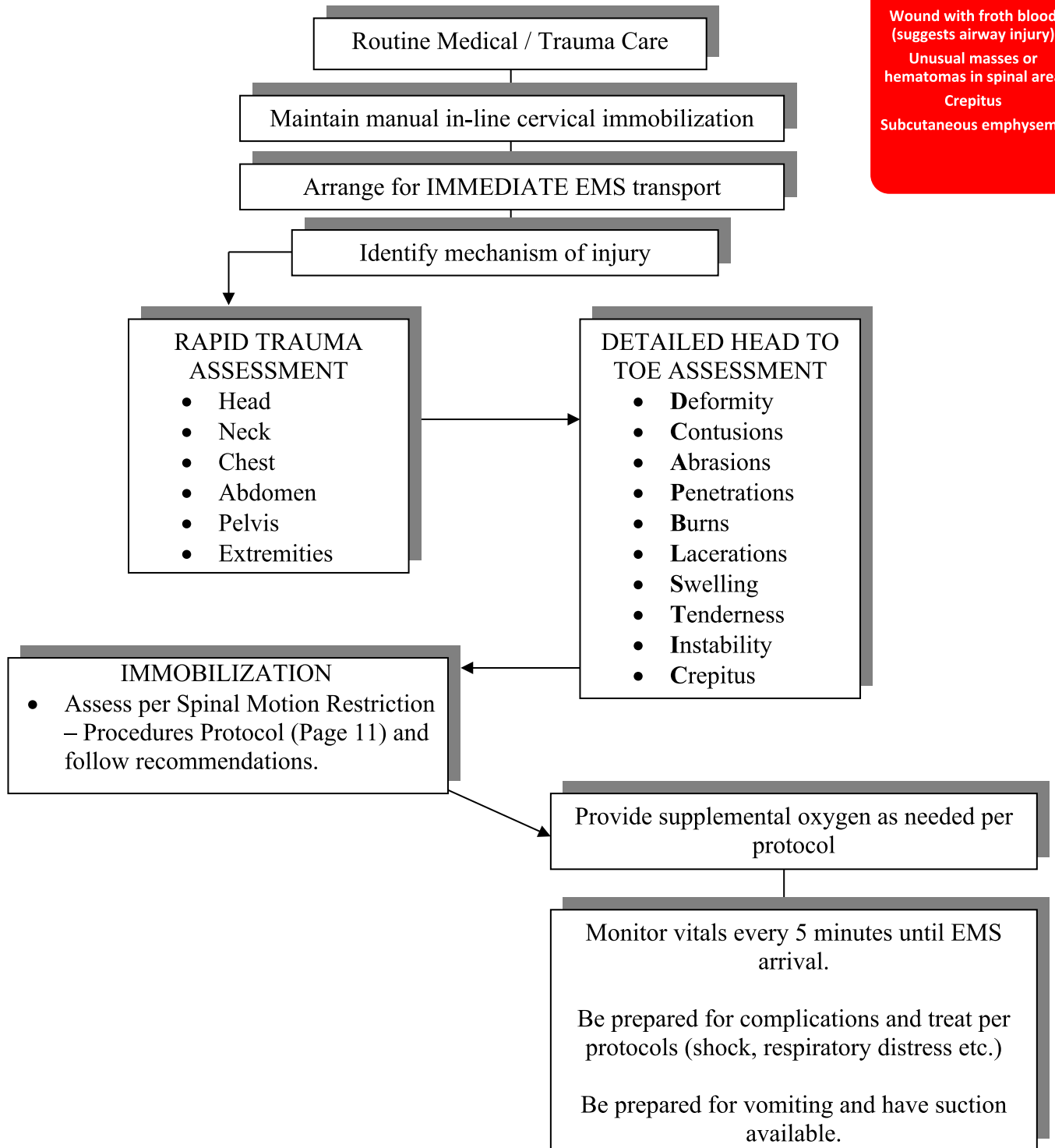


# SPINAL TRAUMA



Neck Swelling  
Discoloration  
Deformity  
Wound with froth blood (suggests airway injury)  
Unusual masses or hematomas in spinal area  
Crepitus  
Subcutaneous emphysema